



MINI-SYMPOSIUM: THE WRIST

(i) Examination of the wrist—surface anatomy of the carpal bones

R. Srinivas Reddy*, J. Compson

Upper Limb Unit, Department of Orthopaedics, King's College Hospital, London SE5 9RS, UK

KEYWORDS

Wrist examination;
Carpal bones;
Surface anatomy

Summary An accurate clinical examination is vital in the diagnosis of wrist injuries. Though various investigations including special X-ray views, computer tomography, and isotope bone scans are used to confirm the diagnosis of carpal bone fractures and wrist ligament injuries, initial diagnosis and localisation is by clinical examination. The fundamental basis of both inspection and palpation is knowledge of surface anatomy. This paper gives a brief overview of carpal osteology and then a method of examination of the carpus which we hope will be used to improve basic examination of the wrist.

© 2005 Elsevier Ltd. All rights reserved.

Introduction

Despite the improvement in imaging techniques and the use of arthroscopy, clinical examination remains the most important step in the diagnosis of wrist injuries. Several common carpal fractures (Table 1) require either special X-ray views, computer tomography or isotope bone scans to confirm the diagnosis. However the initial localisation and recognition of the severity of the injury is by clinical examination. Without this, appropriate use of imaging is impossible and can lead, at best, to unnecessary investigations and, at worse, to a missed diagnosis. This is best illustrated by fractures of the hook of hamate which are rarely

seen on standard X-ray views. The fracture however is easily suspected clinically if one knows the surface anatomy of the hamate though in reality it is often missed. The diagnosis can be confirmed by special oblique views, carpal tunnel views or by isotope bone scanning. However the definitive test which not only diagnoses the fracture but also shows displacement and the state of healing is a CT scan. For similar reasons, as well as being a commonly missed injury, the scaphoid can fracture at three levels and one needs to know how to palpate the tubercle, waist and proximal pole individually to thoroughly examine the bone and pick up all possible fracture types.

Of equal importance some significant ligament injuries, especially when there is no associated dislocation can look surprisingly normal on X-ray (Table 2) and their diagnosis also requires clinical acumen.

*Corresponding author. 5, Derwent close, Gamston, Nottingham NG2 6NF, UK. Tel.: +44 7818 418350.

E-mail addresses: srjayaram@hotmail.com (R. Srinivas Reddy), compsonj@aol.com (J. Compson).

Table 1 Clinically diagnosed carpal fractures and confirmation techniques.

Carpal bone fracture	Investigations
Scaphoid fractures	Special X-ray views, isotope bone scans, MRI scans
Hook of hamate fractures	Special X-ray views and CT scans
Pisiform fractures	Special X-ray views
Trapezium ridge fractures	CT scans
Dorsal flake fractures of the triquetrum	Bone scans

Table 2 Significant ligamentous injuries with 'normal' X-rays.

Ligament injuries	X-ray findings
Acute scapholunate dissociation	Normal
Acute lunotriquetral dissociation	Normal
Thumb carpometacarpal 'Beak' ligament tear	Normal

The basic tenets of examination are look, feel and move. However a vital component in both looking and feeling is knowledge of surface anatomy. Without this the important localisation of carpal injuries is impossible. In a recent study we asked orthopaedic and casualty doctors of all grades to demonstrate the palpation of seven, commonly injured bony landmarks in the carpus. Only two got them all right and none of these was a consultant! Because of this we have written a series of articles on examination of the wrist, which though superficially simplistic we believe are important for both clinical practice as well as examination purposes, especially for those too embarrassed (mainly consultants) to admit they lack the basic knowledge! We have started with surface anatomy since we believe this to be the fundamental basis of examination.

Osteology of the carpus

The carpus contains eight bones in two rows, proximal and distal. The proximal row consists of three bones the scaphoid, lunate, and triquetrum which are attached to each other by intrinsic intercarpal ligaments, the scapholunate and lunotriquetral. They form an arch which is convex proximally and articulates with the radius and the articular disc of the triangular fibro-cartilage complex (TFCC) to form the radio-carpal (wrist) joint. The pisiform, though overlying the triquetrum and articulating with its volar surface, is not

functionally a proximal row bone but is separate and lies in the tendon of flexor carpi ulnaris. The distal row of bones, made up of the trapezium, trapezoid, capitate and hamate, are firmly attached to each other by strong intercarpal ligaments. The distal row articulates with the proximal row to form the midcarpal joint and also articulates with the bases of the metacarpal bones. The distal is more arched than the proximal row with a deep concave volar surface which makes the trapezium lie more palmar than expected compared to the capitate. The ulnar side is deepened by the hook of hamate which produces a deep carpal groove, which accommodates the flexor tendons and the median nerve as they pass into the hand through the carpal tunnel.^{1,2}

Each carpal bone is considered individually.^{1,2}

Scaphoid (Figs. 1A and B—c—e)

The scaphoid has the oddest shape and orientation of all the carpal bones. It lies at about 45° to the long axis of the wrist in both radial and palmar directions. Its proximal end or pole is therefore on the dorsum of the carpus and its distal end, the tubercle, is subcutaneous on the palmar surface. It is a bone of two halves; the proximal is similar to the adjacent lunate with a deep crescentic shape lying tightly in the curve of the scaphoid fossa of the radius and distally, with the lunate, forming a socket holding the head of the capitate. The distal end has a tubercle which is offset and gives an overall twist to the bone which also has a gentle curve in its long axis allowing it to lie between the concave scaphoid fossa of the radius and the convex head of capitate. The waist and distal pole of the scaphoid are not firmly held by adjacent bones and act as a strut transmitting distal row movements to the proximal bones.

Lunate (Figs. 1A and B—f)

The lunate is semilunar and has a convex proximal surface that articulates with the radius and TFCC

and its distal surface is deeply concave to fit the ulnar side of the head of the capitate. The articulation between the three bones, capitate, scaphoid and lunate, forms a ball and socket in the middle of the mid-carpal joint. Most of the bone, like the proximal pole of the scaphoid, when the wrist is in a neutral position, lies under the cover of the dorsal rim of the radius and cannot be palpated. It is uncovered by flexion of the wrist.

Triquetrum (Figs. 1A and B—g)

The triquetrum is somewhat pyramidal and bears an oval facet on its palmar surface for articulation with the pisiform. It articulates laterally with the lunate and distally with the hamate. The bone lies more distally and obliquely than expected and moves by sliding on its flat articular surfaces. It has a dorsal tubercle which is commonly fractured.

Pisiform (Figs. 1A and B—h)

The pisiform is like a small patella lying in the tendon of flexor carpi ulnaris. It increases the distance of the FCU from the centre of rotation of the wrist and thus improves the lever arm and therefore the strength of the muscle. This is the same function the patella has in the knee and the pisiform has all the pathologies found in its larger brother.

Trapezium (Figs. 1A and B—m and n)

The trapezium is larger than is normally assumed, which is why trapeziectomies seem to keep going on forever! It also lies more volar than any other

carpal bone. It articulates proximally with the scaphoid, distally with the thumb and index metacarpals and medially with the trapezoid. There is a prominent ridge and tubercle with a groove lying obliquely on the palmar surface. The ridge is part of the fibro-osseous sheath of flexor carpi radialis and can be fractured after a fall on the outstretched hand since it is the first part of the carpus to hit the ground.

Trapezoid (Figs. 1A and B—l)

The trapezoid articulates distally mainly with the metacarpal base of the index finger and proximally with the scaphoid. Laterally it articulates with the trapezium and medially with the capitate and is difficult to palpate.

Capitate (Figs. 1A and B—k)

The capitate is the largest carpal bone and articulates distally mainly with the middle metacarpal base and proximally with the scaphoid and lunate. Laterally it articulates with the trapezoid and medially with the hamate. The proximal end is ball shaped and is difficult to palpate individually.

Hamate (Figs. 1A and B—i and j)

The most important part of the hamate to examine is the hook projecting from the distal part of its palmar surface. It is much larger than one would assume from palpation or X-rays.

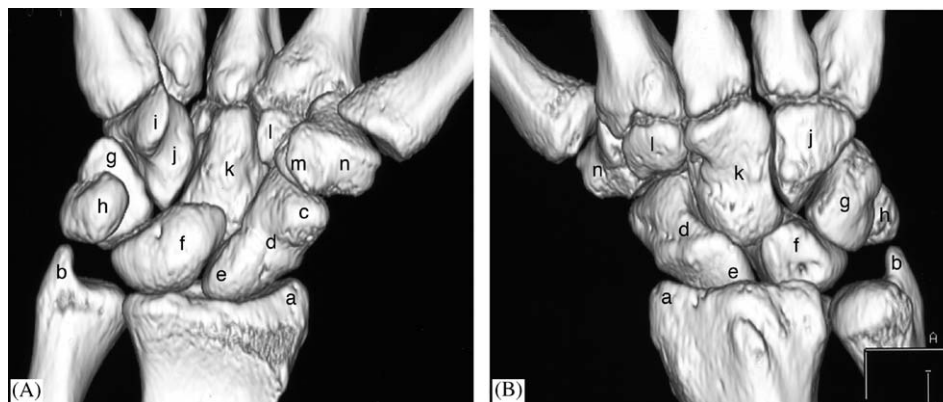


Figure 1 Palmar (A) and dorsal view (B) of the carpus describing the osteology. Landmarks on the 3D CT reconstruction are—(a) radial styloid, (b) ulnar styloid, (c) scaphoid tubercle, (d) waist of scaphoid, (e) proximal pole of scaphoid, (f) lunate, (g) triquetrum, (h) pisiform, (i) hook of hamate, (j) hamate, (k) capitate, (l) trapezoid, (m) tubercle of trapezium, (n) trapezium.

Surface anatomy landmarks

The following routine is used by the senior author to teach and demonstrate the surface anatomy of the carpal bones. We believe it is worth going through each step examining the right wrist with the left hand. To simplify orientation all the illustrations are of the right wrist. The various landmarks are numbered in the adjoining figures and the best way to understand is to closely correlate the figures with the text descriptions.

Dorsal view of the carpus and the wrist (Figs. 2A and B)

The starting point is Lister's tubercle (1) which lies on the dorsal surface of the distal radius in line with the web space between the index and middle

fingers. It is normally easily palpable using the pulp of the thumb; however if one has problems feeling it, if one extends the wrist it is normally at the level of the most proximal extensor skin crease. It is felt as a small longitudinal ridge in the long axis of the forearm. It can also be found by extending proximally by about 2 cm the line of extensor pollicis longus on the back of the hand and is felt just radially to where the tendon lies.^{3,4}

The next move is to slide the thumb about 1–2 cm distally towards the fingers. The tip of the thumb should fall into a soft depression just distal to the dorsal rim of the radius (Figs. 3A and B). This has been called the crucifixion fossa (2).^{5,6} This fossa can also be located by following the line of the web space between the index and middle fingers proximally until it falls into the same depression just distal to the radius. We are not sure of the origins of the name, crucifixion fossa; however it was first heard by

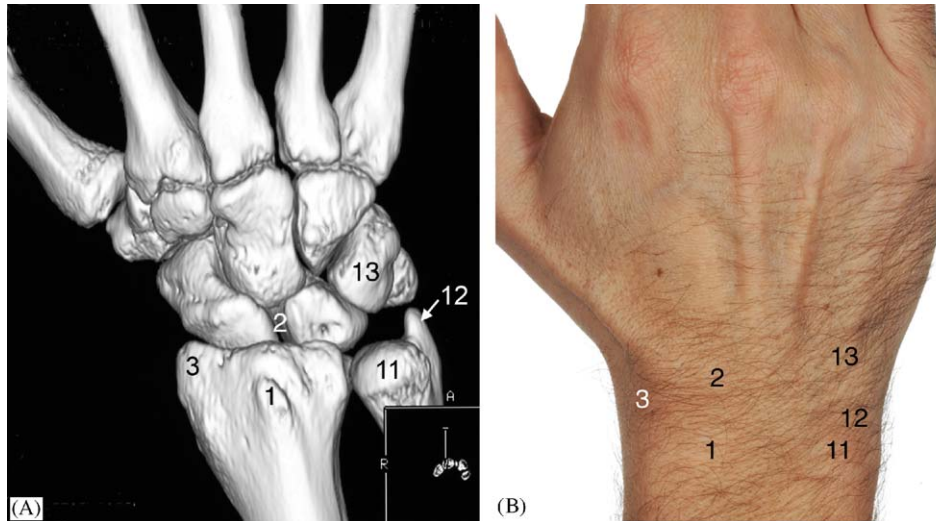


Figure 2 Dorsal view of the carpus and wrist as 3D CT reconstruction (A) and clinical photograph (B). Landmarks in both figures are—(1) Lister's tubercle, (2) crucifixion fossa at the level of the scapholunate junction, (3) radial styloid process, (11) head of ulna, (12) ulnar styloid process, (13) triquetrum.

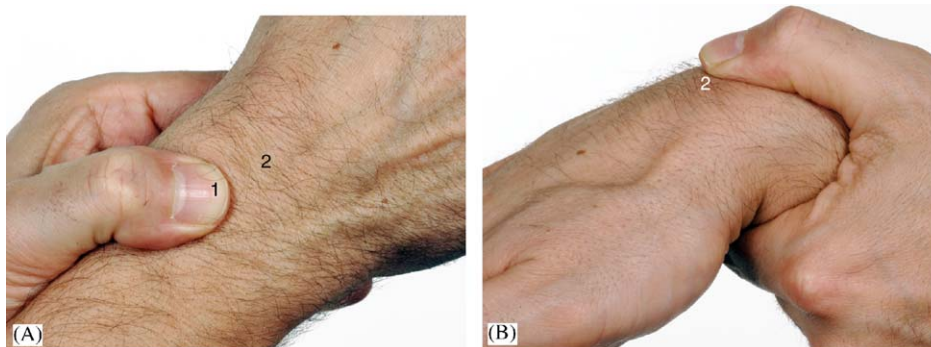


Figure 3 (A) Palpation of the Lister's tubercle, (B) palpation of the lunate and scapholunate junction with the wrist in flexion. Landmarks are—(1) Lister's tubercle, (2) crucifixion fossa at the level of scapholunate junction.

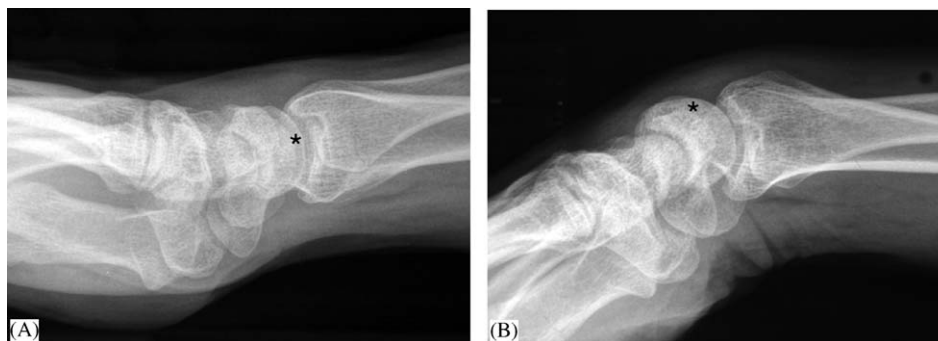


Figure 4 X-rays of lateral views of the wrist in neutral (A) and in palmar flexion (B). The asterisk (*) symbol in both the views indicates the position of the lunate and the proximal pole of scaphoid with the scapholunate junction in between them, and they are more prominent with the wrist in flexion.

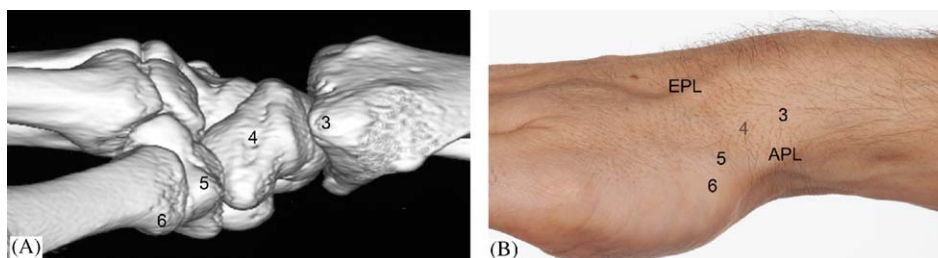


Figure 5 Lateral (radial) view of the carpus and wrist as 3D CT reconstruction (A) and clinical photograph (B). Landmarks in both figures are—(3) radial styloid, (4) waist of scaphoid, (5) trapezium, (6) base of the first metacarpal, EPL: extensor pollicis longus, APL: abductor pollicis longus and extensor pollicis brevis.

one of the authors in a talk by Professor John Stanley. It is probably named such since it lies almost directly over the scapholunate joint and a nail introduced here will produce a clinically significant scapholunate dissociation which would not cut out with load. The capitate and the rest of the strongly joined distal carpal row would prevent this. The Romans probably knew their anatomy better than we do! The tip of the thumb is now at about the level of the mid-carpal joint since the proximal row is under the rim of the radius. If the wrist is now flexed with the tip of the thumb still in the crucifixion fossa one will feel a hard lump coming up into the recess. This is the proximal row and the thumb is now over the area of the scapholunate joint. Ulnarwards, the adjacent radial side of the lunate and radially the proximal pole of the scaphoid can be felt, depending on the degree of ulnar or radial deviation (Figs. 4A and B).^{7,8}

Lateral (radial) view of the carpus and the wrist (Figs. 5A and B)

Moving the thumb radially along the dorsal rim of the radius one crosses the sheath of extensor pollicis longus until it eventually comes to the radial styloid (3). You will have noted that it lies volar to the long axis of the radius. This means that

a K-wire driven through its tip into the radius is likely to come out of the back of the bone. This is worth noting the next time one wires a distal radial fracture. Moving the thumb distally, one enters the soft recess of the anatomical snuffbox. The radial rim is the base of a triangle and one can easily palpate its radial (anterolateral) border which is formed by the abductor pollicis longus and extensor pollicis brevis and its ulnar (posteromedial) border which is formed by the extensor pollicis longus. The floor of the snuffbox is formed by (proximal to distal) the radial styloid process, the waist of the scaphoid (4), the trapezium (5) and the base (6) of the thumb metacarpal. With the wrist in a neutral position it is difficult to feel the scaphoid or trapezium. If one places the thumb tip into the snuffbox and then ulnar deviates the wrist, bone can be felt filling the recess. This is mainly the waist and the non-articular dorsal ridge of the scaphoid, though one can also feel part of the trapezium (Figs. 6A and B).³⁻⁵

Palmar view of the carpus and the wrist (Figs. 7A and B)

Moving to the palmar side of the wrist the thumb tip crosses the first dorsal compartment

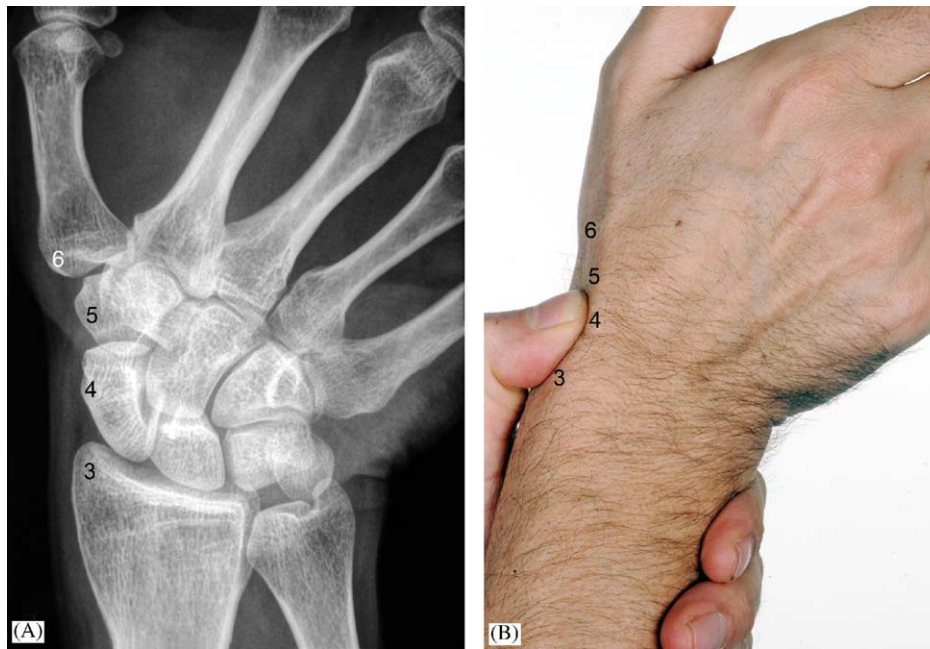

Figure 6 Anatomical snuffbox is revealed better with the wrist in ulnar deviation. (A) X-ray of wrist in ulnar deviation, (B) clinical photograph of wrist in ulnar deviation. Landmarks are—(3) radial styloid, (4) waist of scaphoid, (5) trapezium, (6) base of the first metacarpal.

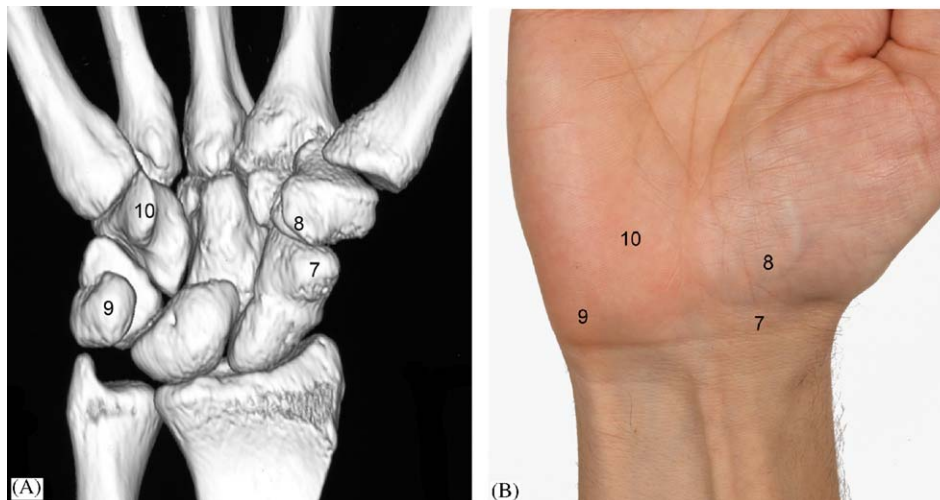


Figure 7 Palmar view of the carpus and wrist as 3D CT reconstruction (A) and clinical photograph (B). Landmarks in both figures are—(7) tubercle of the scaphoid, (8) tubercle of trapezium, (9) pisiform, (10) hook of hamate.

[De Quervain's tendons] until it feels the radial pulse. Moving distally the thumb again falls into a soft recess bordered ulnarwards by the tendon of flexor carpi radialis. Moving more distally and at the level of the distal flexor crease lies a bony prominence. This is the tubercle of the scaphoid (7) which can be more easily palpated by extending the wrist. If one now places the left index finger tip on the tubercle and also one's thumb in the crucifixion

fossa on the back of the wrist which is over the proximal pole of the scaphoid you will be holding both ends of the scaphoid. One will note how it lies at 45° to the long axis of the wrist in both a palmar and radial direction. If one then radially deviates the wrist and keeps the thumb and finger in the same place on the bone one can see and feel how the scaphoid flexes. If one then ulnar deviates the wrist it does the opposite and the scaphoid can be

felt lying in a more extended position. If one now again places the thumb on the tubercle of the scaphoid and moves distally under the cover of the thenar muscles one can feel the tubercle and ridge of the trapezium (8), facilitated by deviating the wrist ulnarwards.²⁻⁵

Keeping on the palmar side of the wrist but moving across the carpal tunnel to the ulnar side one can easily palpate the pisiform bone (9). This was the most consistently demonstrated bone in our study. The pisiform forms an elevation, which can be seen and felt on the palmar aspect of the wrist at the base of the hypothenar eminence (Figs. 8A and B). It lies just distal to the most medial end of the distal wrist crease at the ulnar border. The next manoeuvre is to place one's thumb over the pisiform and move it distally by about 2 cm and then towards the mid-line by about a centimetre. Your thumb should be in the line of the ring finger. Deeply under the hypothenar muscles one can feel a large and solid bony lump which is the clinically important hook of hamate (10). It is not easy to feel and may require firm pressure to do so but anyone treating carpal injuries should be able to palpate this part of the bone.²⁻⁵

Medial (ulnar) view of the carpus and wrist (Figs. 8A and B, 9A and B)

Moving back to the dorsum of the wrist but this time on the ulnar side and palpating with the index finger. Start with the head of the ulna (11) which is easily visible and forms an elevation on the dorsal and medial aspect of the wrist especially when the wrist is pronated.

With the wrist in pronation move the finger tip ulnarwards across the ulnar head until you can feel the tendon of extensor carpi ulnaris overlying the bony prominence of the ulnar styloid (12). Keeping the finger on the tendon and supinating and pronating the wrist the tendon can be felt rolling around the ulnar head and appreciate how the

ulnar styloid becomes more dorsal on supination and volar on pronation. Moving the finger tip distally from the ulnar styloid one again enters a soft recess 'The Ulnar Snuffbox'. This is more difficult to palpate than the anatomical snuffbox but the sides can be felt better by ulnar deviating the wrist. Dorsally one can feel the tendon of extensor carpi ulnaris (14) and volarwards the flexor carpi ulnaris (15). The triquetrum (13) is in the base of the fossa and can be found distal to the ulnar styloid process: it is felt more easily by first deviating the wrist (Fig. 9B) ulnarwards, placing the fingertip into the soft recess distal to the ulnar styloid then moving the wrist into radial deviation. The triquetrum is felt moving under the finger.⁴⁻⁶ Moving the fingertip onto the dorsum of the wrist at the same level, one can palpate the dorsum of the triquetrum (Fig. 9A). Here lies a small tubercle which is not easily felt but is commonly knocked off in hyperextension injuries and appears as a flake on lateral X-rays. Localisation however requires clinical examination.

The volar surface of the triquetrum cannot be directly palpated due to the overlying pisiform; however it can be tested for tenderness by indirect force through the pisiform. It is important to exclude pisiform tenderness which can be elicited by pushing the pisiform from the ulnar side.

This covers all the bones in the proximal row except for the lunate which is difficult to palpate due to the overhang of the radial rim and the overlying extensor tendons, even when the wrist is flexed.

Distal row

The last part of the examination is to palpate the distal row. Apart from the tubercle of the trapezium and the hook of hamate this needs to be done from the dorsum. Though one has difficulty in exactly differentiating each bone precisely their positions can be worked out by following the

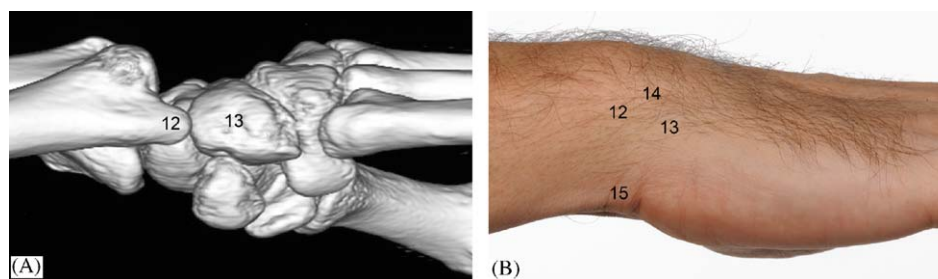


Figure 8 Medial (ulnar view) of the carpus and wrist as 3D CT reconstruction (A) and clinical photograph (B). Landmarks in both figures are—(12) ulnar styloid, (13) triquetrum, (14) extensor carpi ulnaris, (15) flexor carpi ulnaris.

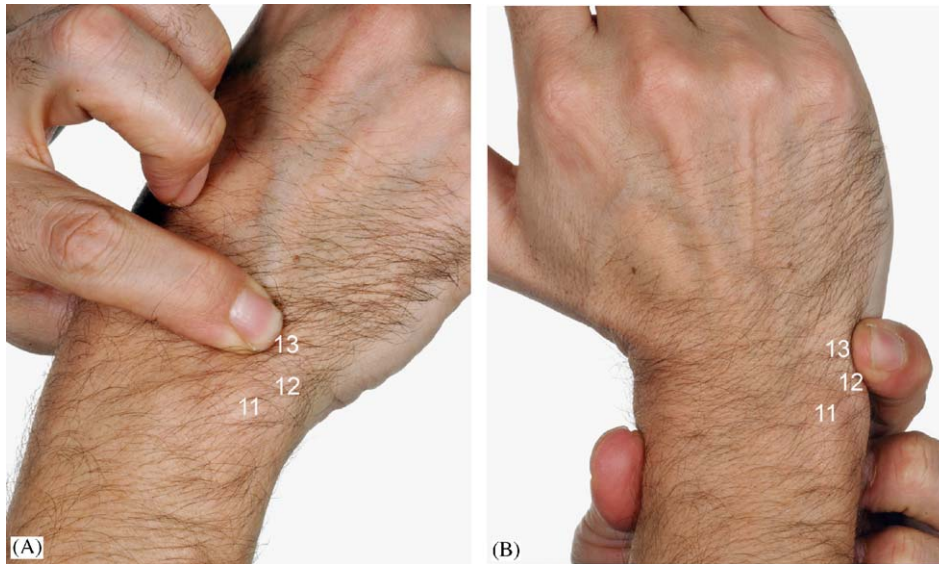


Figure 9 (A) Palpation of the dorsal aspect of triquetrum with the wrist in neutral position, (B) Palpation of the triquetrum in the ulnar snuff box with the wrist in radial deviation. Landmarks in both figures are—(11) head of ulna, (12) ulnar styloid process, (13) triquetrum.

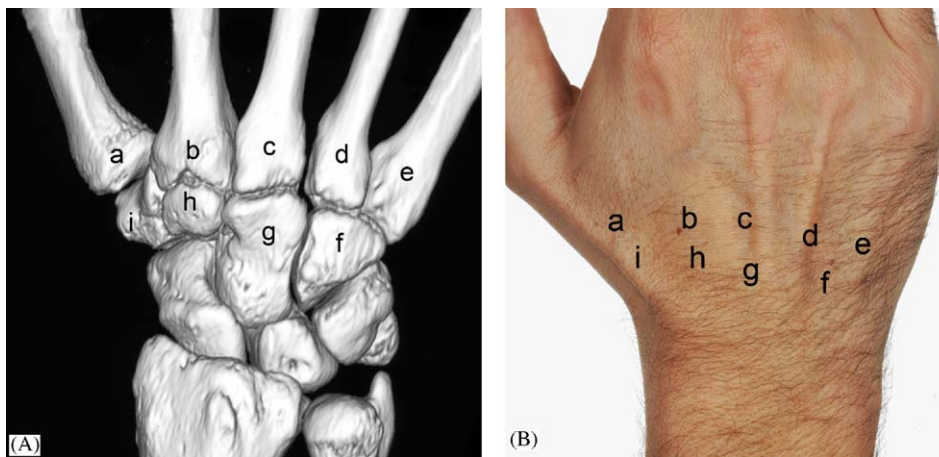


Figure 10 Dorsal view of the wrist and carpus as 3D CT reconstruction (A) and clinical photograph (B), following the metacarpals to their bases towards the carpometacarpal joints. Landmarks in both the figures are—(a) thumb (1st) metacarpal, (b) index finger (2nd) metacarpal, (c) middle finger (3rd) metacarpal, (d) ring finger (4th) metacarpal, (e) little finger (5th) metacarpal, (f) hamate, (g) capitate, (h) trapezoid, (i) trapezium.

associated metacarpal shafts proximally to the base and then on to the adjacent carpal bone (Figs. 10A and B). If the wrist and digits are placed in flexion, it may be easier to palpate the carpal bone having eliminated the overhang of the metacarpal base. At the base of the thumb metacarpal is the trapezium. At the base of the index metacarpal is the trapezoid; the capitate is found at the base of the middle finger. The hamate can be located by following both the ring and little finger metacarpals to their bases since they both articulate with the hamate in a single joint.

References

1. Sinnatamby SC. Osteology of the upper limb. In: Sinnatamby SC, editor. *Last's anatomy*. Edinburgh: Churchill Livingstone; 1999. p. 103–4.
2. Soames WR. *Skeletal system*; Ellis H, Dussek EJ. *Surface anatomy*. In: Williams LP, editor. *Gray's anatomy*. New York: Churchill Livingstone; 1995. p. 646–649, 1926–1928.
3. Borley NR. Upper limb. In: Borley NR, editor. *Clinical surface anatomy*. London: Manson Publishing Ltd; 1997. p. 50–6.
4. Keogh B, Ebbs S. The upper limb. In: Keogh B, Ebbs S, editors. *Normal surface anatomy*. London: William Heinemann Medical Books Ltd; 1984. p. 114–5.

5. Saffar P. Clinical examination of the wrist. In: Saffar P, editor. *Carpal Injuries, anatomy, radiology, current treatment*. Paris: Springer; 1990. p. 11–6.
6. Ritchie JV, Munter DW. Emergency department evaluation and treatment of wrist Injuries. *Emerg Med Clin North Am* 1999;17(4):823–42.
7. Weinzweig J, Watson KH. Examination of the wrist. In: Weinzweig J, Watson KH, editors. *The wrist*. Philadelphia: Lippincott Williams & Wilkins; 2001. p. 48–59.
8. Rex C. Examination of wrist. In: Rex C, editor. *Clinical assessment and examination in orthopaedics*. New Delhi: Jaypee Brothers Medical Publishers (P) Ltd; 2002. p. 47–55.

Available online at www.sciencedirect.com

